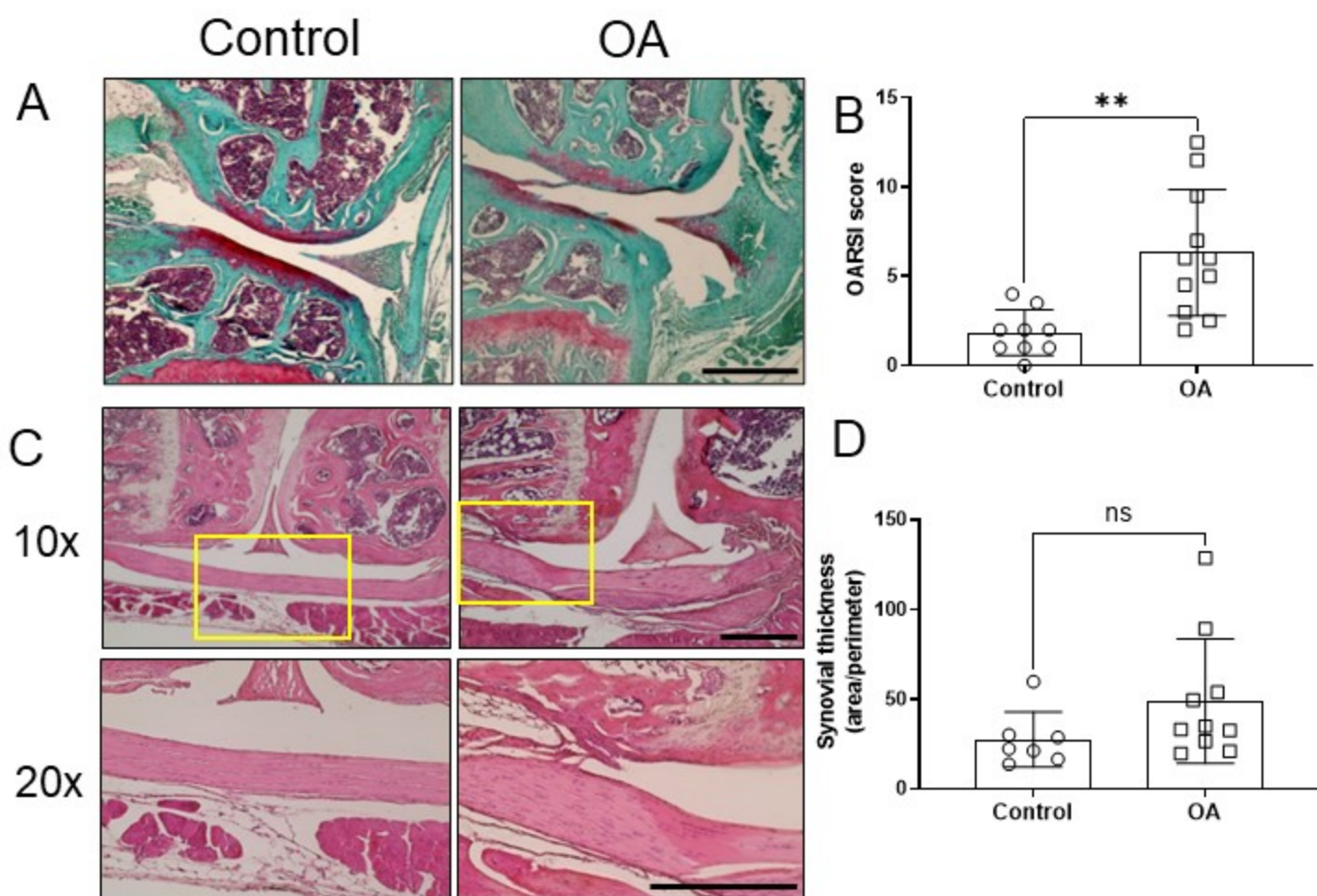


Supplementary figure 2



Supplementary figure 2 - **Cartilage degradation and fibrillation, but not synovial hyperplasia, are visible 8 weeks after DMM surgery.** Mice subjected to DMM (OA group) or control surgery (Control group) were sacrificed after 8 weeks. The knees were collected for histological assessment. Representative images of the knee articular surfaces stained with the safranin-O/fast green staining (A, scale bar = 500 μ m) and plotted OARSI score quantification (B). Representative figures of H&E staining of the knee joint (C, 10x magnification on the top section, 20x magnification on the bottom section, scale bar = 500 μ m) and quantification of the synovial thickness (synovial area/perimeter; D). Data are expressed as mean \pm SD and analyzed by t-test. ** p <0.01, ns = not statistically significant.